

SPECIALIST PAEDIATRIC RADIOLOGY UPDATE

MIA Victoria specialises in the imaging needs of children. Three consultant radiologists with extensive paediatric imaging experience are always available for consultation. This Paediatric Update will outline our imaging recommendations for common paediatric conditions.

CHILDHOOD URINARY TRACT INFECTION – CURRENT IMAGING RECOMMENDATIONS



Assoc Prof Michael Ditchfield
Paediatric Radiologist
MBBS MD FRANZCR

Urinary tract infection (UTI) in children is a common condition and important because of its association with potentially important pathology. Unfortunately, when the literature on UTI, vesicoureteric reflux (VUR) and renal scarring is analysed, the basis for the diagnosis, investigation and management of childhood UTI is of very poor scientific quality. Renal scarring was first identified in children in 1939, and 50 years ago a relationship between renal scarring and VUR was observed. At that time, micturating cystourethrography (MCU) became available to diagnose VUR and surgical techniques to correct VUR were developed.

Until 1985, the pathogenesis of renal scarring seemed simple and well understood. It was thought that VUR transported infected urine to the kidney where intrarenal reflux resulted in renal parenchymal infection (acute pyelonephritis) and renal scarring. However, the causal relationship between VUR and scarring has never been proven and is probably a rare occurrence with acute pyelonephritis most commonly occurring in the absence of VUR.

The radiological examinations, surgery and subsequent antibacterial prophylaxis were all introduced without controlled trials to demonstrate their clinical effectiveness. This has created much confusion and conflict of opinion concerning the investigation and management of UTI, VUR and related conditions.

PATHOLOGY

Over half of children with a single UTI under the age of five years will have an abnormality of the renal tract. The abnormalities are:

1. Obstruction – either pelviureteric (Fig. 1 & 2), vesicoureteric or, in boys, urethral and all usually require surgery.
2. Scarring – can be congenital (renal dysplasia) or acquired following acute pyelonephritis, which is probably a rare occurrence. Scars are important because some, but not all, children with scars will have long term sequelae such as hypertension and renal impairment. Once a scar is diagnosed regular blood pressure monitoring and urinalysis is required.
3. Vesicoureteric reflux (Fig 3.) – is associated with congenital scarring (renal dysplasia) and is a potential precursor of acquired renal scarring by predisposing to acute pyelonephritis (probably a rare occurrence).
4. Acute pyelonephritis – occurs more commonly in the absence of VUR and is a possible precursor of acquired renal scarring.

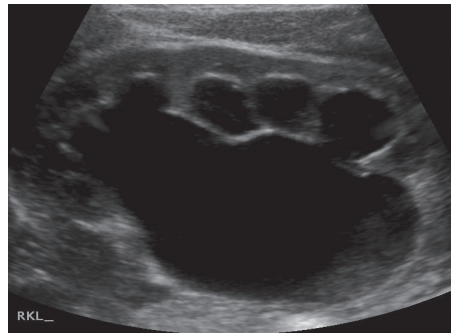


Fig 1. Renal ultrasound demonstrating severe hydronephrosis secondary to pelviureteric obstruction.

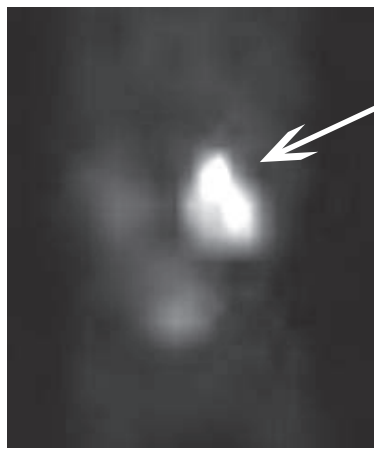


Fig 2. Mag 3 scan following Lasix washout demonstrating delayed drainage of isotope from the left kidney (arrow)

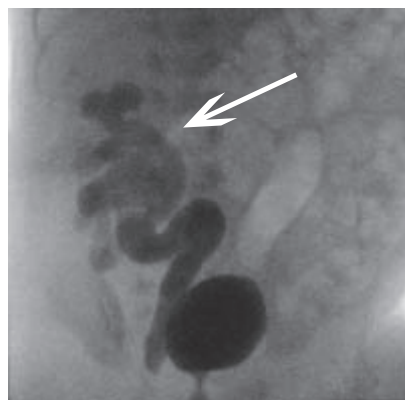


Fig 3: MCU demonstrating right Grade 4 Vesicoureteric Reflux (arrow).

IMAGING

It is important to identify renal obstruction and scarring, and all children with a single microbiologically proven UTI should therefore be investigated. The imaging recommendations have evolved significantly over the past 10 years. The current recommendation is that all children should have a renal ultrasound (US) after the first UTI and further investigation will depend on the US findings. **Renal Ultrasound** is a simple non-invasive method of screening for both obstruction (Fig 1) and scarring

when performed by experienced diagnosticians with high quality equipment. If there is significant pelvicalyceal dilatation, a nuclear medicine **DTPA (Diethylenetriamine-penta acetic acid) scan** or **Mag 3 (Mercaptoacetyl triglycine) scan** (Fig 2) should be performed to exclude obstruction. Renal ultrasound may identify renal scarring or suggest the need for further investigation. If the ultrasound demonstrates a significant renal size discrepancy, or one or both kidneys are small, a **DMSA (Dimercaptosuccinic acid) scan** should be performed because it is very sensitive in diagnosing renal scarring. The US may also diagnose acute pyelonephritis or suggest the diagnosis if one kidney is enlarged. In this circumstance the US should be repeated after 6 months after the acute inflammation has resolved.

The primary role of micturating cystourethrography is to detect vesicoureteric reflux (Fig 3). Previously this had been recommended for all children under five years of age with UTI. Even in the best hands, it is an invasive and distressing procedure and the importance of diagnosing VUR is now being questioned. The current Royal Children's Hospital Clinical Practice Guidelines advise that a "Micturating cysto-urethrogram may be necessary but the decision to perform this invasive and sometimes distressing investigation needs to be individualised. The value of demonstrating vesicoureteric reflux in assisting future management is controversial. It is currently a matter of physician preference. It may be done in children under 6 months of age (especially boys), and may be necessary for older children according to circumstances." It may be necessary in older children in some circumstances when it could alter the management of the child as a preoperative work up (e.g. frequent recurrent UTI, abnormal US). An **Indirect Radionuclide MCU**, which is performed as part of a nuclear medicine DTPA scan, does not require catheterisation of the child and is a reasonable, less invasive alternative in diagnosing VUR in children that are toilet trained.

There are now very few indications for performing an **Intravenous Pyelogram (IVP)** in children as other investigations provide more information with a lower radiation dose.

CONCLUSION

Lack of scientific data has created much confusion and conflict of opinion concerning the diagnosis, investigation and management of childhood urinary tract infection and its related conditions. Nevertheless, UTI in children is common and important because of its association with obstruction and scarring. All urinary tract infections in children require investigation with a renal ultrasound, with further imaging dictated by the ultrasound findings and the clinical setting.

We have a pamphlet which explains the procedures in words that parents can understand and explain to their children. If you would like some pamphlets and maps of our paediatric imaging locations for your practice, please contact Danielle Browne on 9804 6112.

If you have any queries regarding any of the information detailed above or any other aspect of paediatric radiology, please do not hesitate to contact myself or any of our paediatric radiologists.